

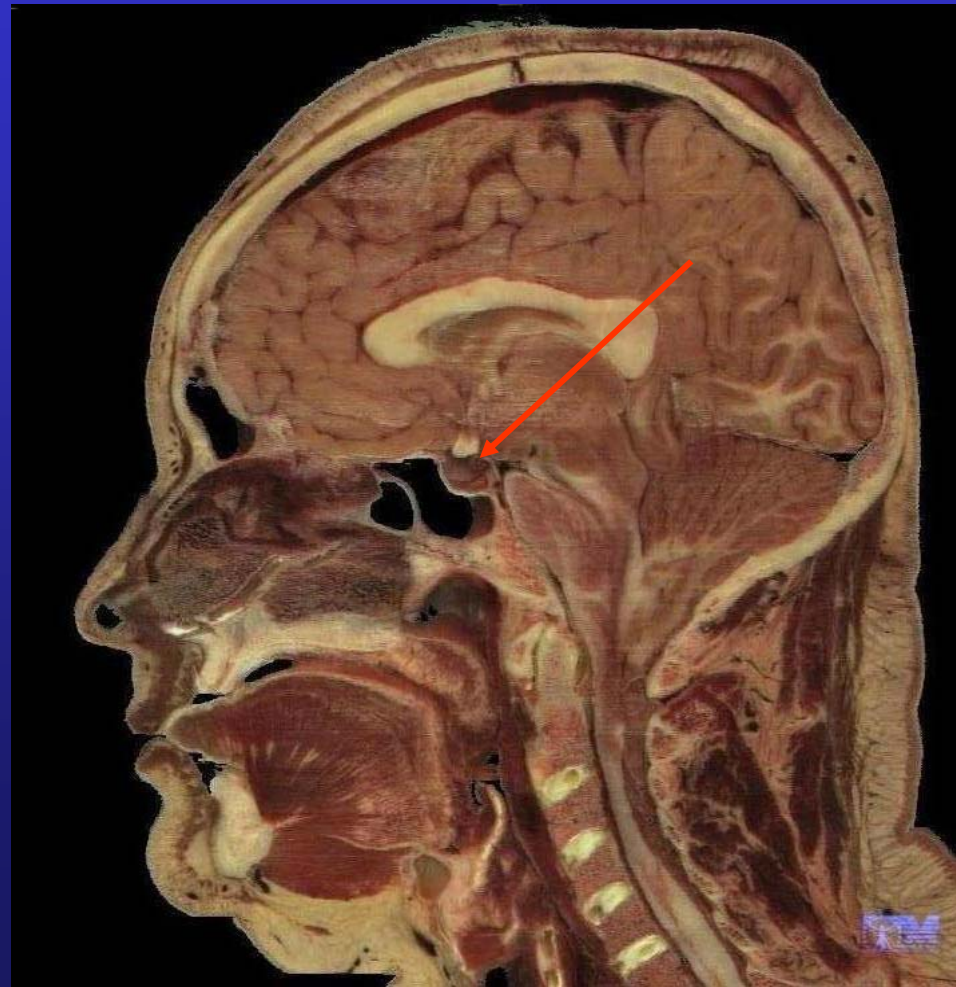
The Surgical Management of Pituitary tumours
Indications, techniques, results and complications

Mr Nigel Mendoza
Consultant Neurosurgeon
Charing Cross Hospital

Pituitary surgery : Anatomical considerations

Pituitary gland

- **Position**
 - Pituitary fossa
- **Mass** : 5 gms
- **Size**
 - 7mm (Ht)
 - 9mm (AP)
 - 11mm (transverse)

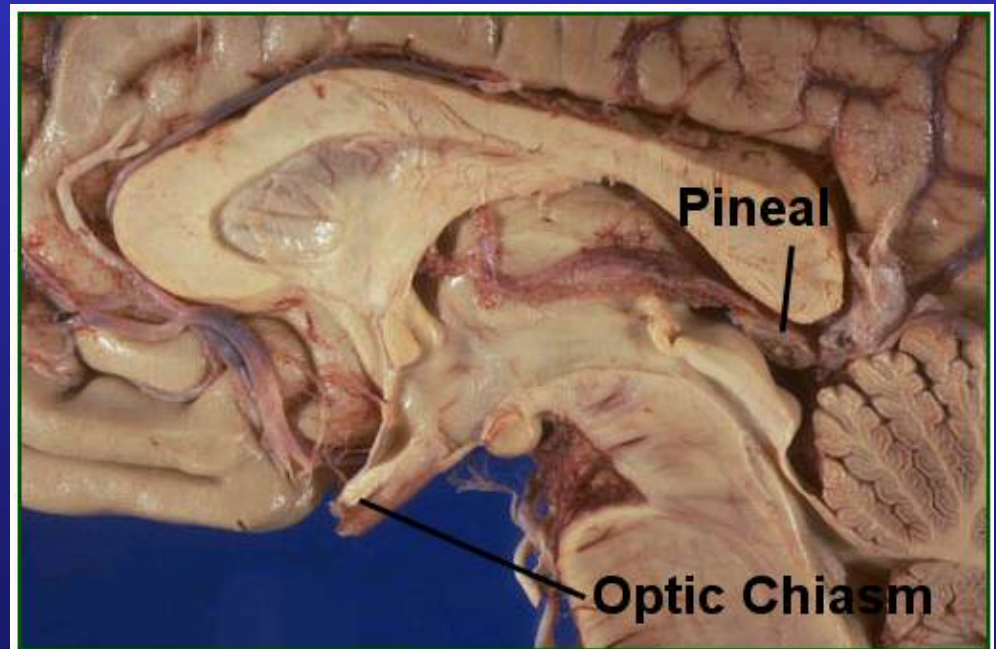


Tumours of the pituitary fossa

- Adenohypophyseal tumours
 - Pituitary adenoma
 - Non - functioning
 - Functioning
- Primary sellar tumours
 - Craniopharyngioma
 - Chordoma
 - Teratoma
 - Meningioma
 - Angioma
 - Fibroma
 - Glioma
- Hamatoma
- Germinoma
- Paraganglioma
- Sarcoma
- Ganglioglioma
- Metastasis
 - Carcinoma
 - Sarcoma
 - Lymphoma
- Congenital
 - Rathkes pouch cyst

Clinical presentation : Mass effect

- Visual disturbances
 - Visual field defect
 - usually very insidious and slowly progressive
 - Diplopia
 - Visual acuity
 - Hydrocephalus
 - Gait disturbance
 - Headache
 - Cranial nerve palsies
-
- Raised intracranial pressure



Clinical presentation : Hypersecretion

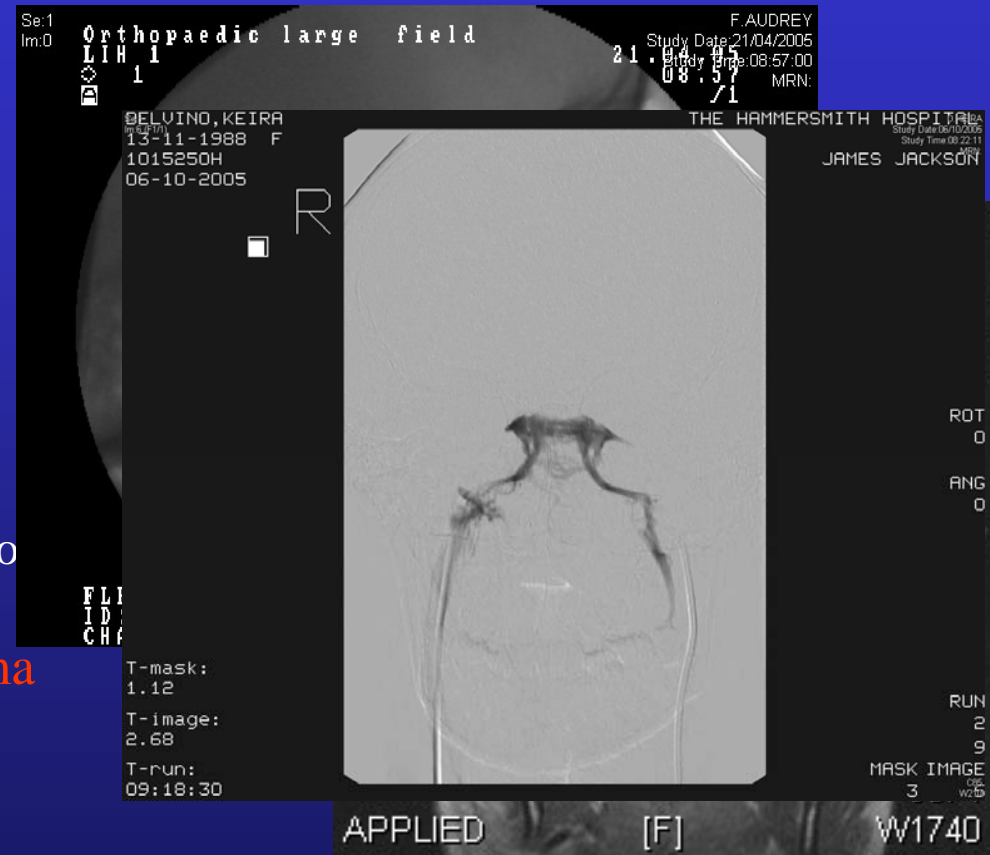- Prolactin
 - Galactorrhoea , amenorrhoea, osteoporosis
- G.H
 - Acromegaly, organomegaly, D.M, CTS
- ACTH
 - Cushing's disease, Diabetes mellitus, osteoporosis, obesity, hypertension
- TSH
 - Hyperthyroidism, cardiac dysrhythmia, heat intolerance

Clinical presentation : Pituitary apoplexy

- Acute presentation secondary to tumour haemorrhagic necrosis
 - Headache
 - Vomiting
 - Blindness
 - Ocular paresis
 - Altered level of consciousness

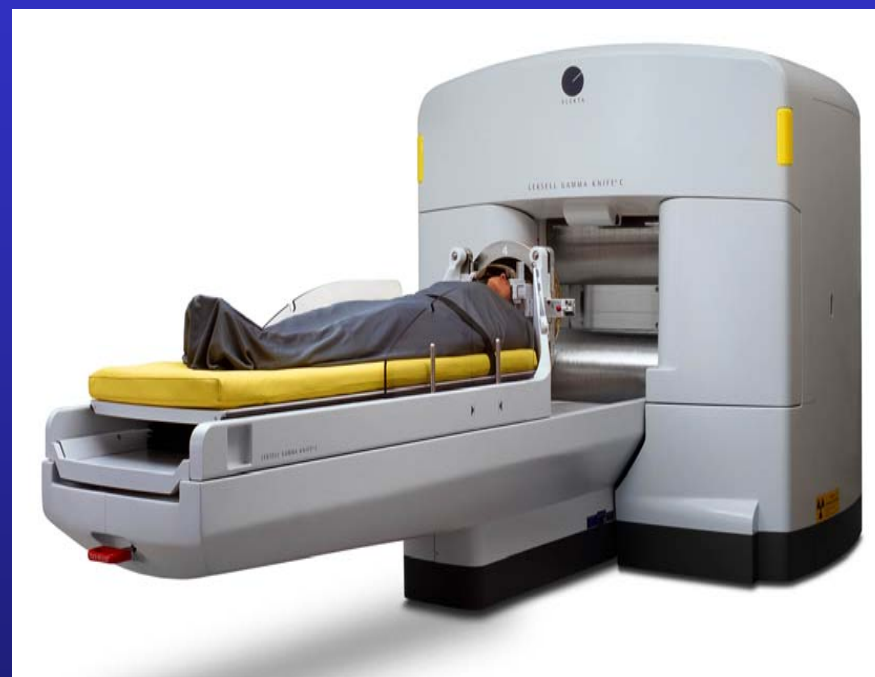Imaging of Pituitary tumours

- X - Ray
 - Sellar expansion
- MRI
 - Tumour volume
 - Suprasellar extension
 - Chiasmatal compression
 - Tumour shape
 - ‘cottage loaf’
 - Lateral extension into cavernous sinuses
 - Signal characteristics
 - Aneurysm, meningioma
- CT
 - Sphenoid sinus anatomy
- IPSS
 - Lateralises an adenoma in about 70 - 80% of cases



Modalities of treatment

- Medical
 - Dopamine agonist
 - Octreotide (? Pre op)
 - Replacement therapy
- Surgery
 - Transphenoidal
 - Transcranial
- Radiotherapy
 - Conventional fractionated external beam
 - Stereotactic gamma knife radiosurgery
 - Interstitial brachytherapy / photodynamic therapy



Indications for surgery

- Tumour with mass effect (Macroadenoma : > 1cm)
 - Chiasmal compression and objective visual field defect
 - Raised intracranial pressure
- Pituitary dependant Cushing's disease
- GH secreting tumour
- Prolactinoma
 - Failure of medical of treatment
 - Intolerance of medical management
 - Pt preference
- TSHoma
 - Thyrotoxicosis

Recent innovations

- Intraoperative stereotactic neuronavigation

Frameless stereotaxy for TS surgery. Elias W, Chaddock J, Alden T, Laws E. Neurosurgery 45: 271 - 277, 1999

- Endoscopic assisted transphenoidal surgery

Transnasal - transphenoidal endoscopic surgery of the pituitary gland . Carrau R, Jho H, Ko Y. Laryngoscope 106 : 914 - 918, 1996

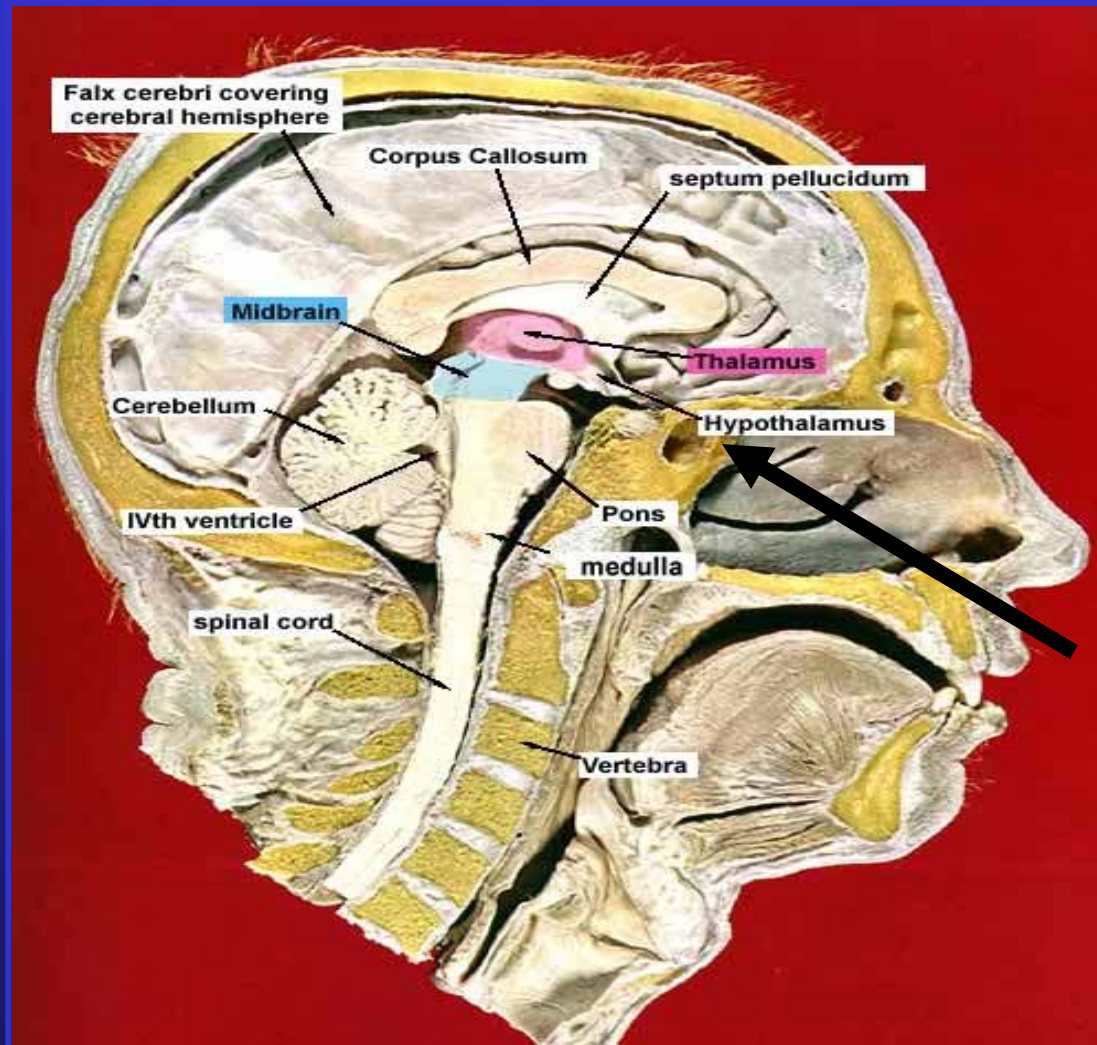
- Stereotactic radiosurgery

- Technical improvements

- Extended skull base approaches
- Reconstruction of skull base

- Intraoperative magnetic resonance imaging

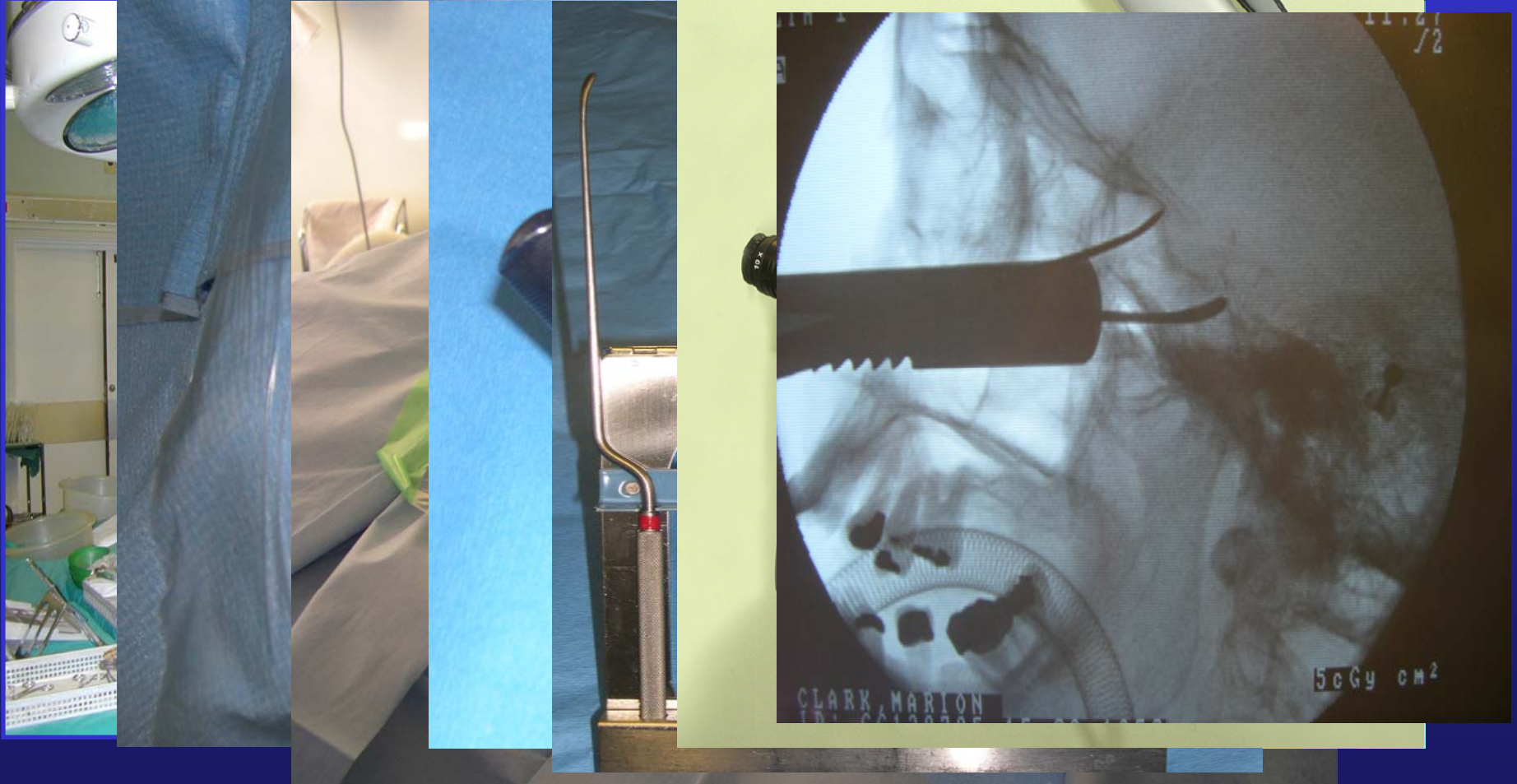
Transsphenoidal approach to pituitary fossa



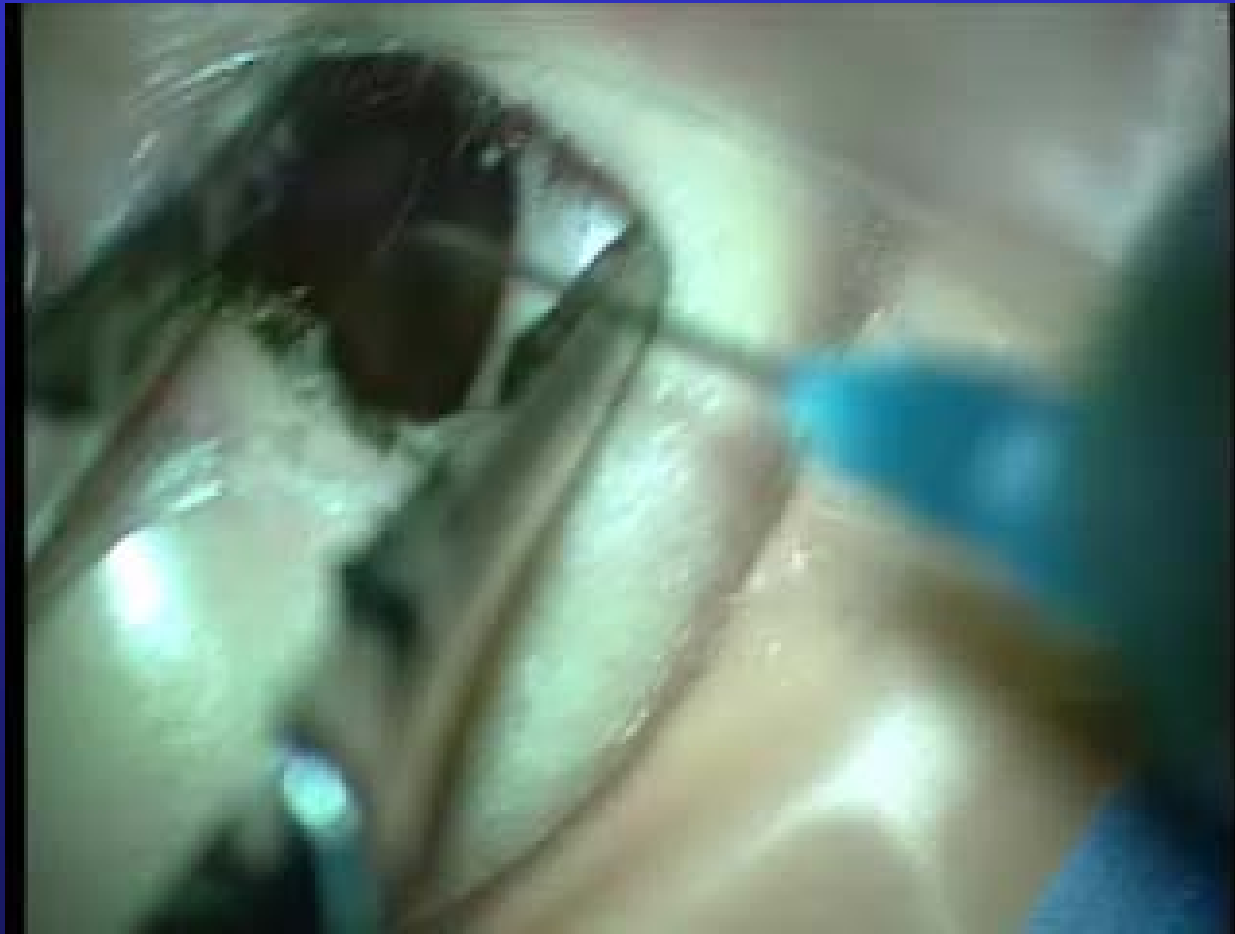Approaches to pituitary fossa lesions

- Transsphenoidal
 - Transnasal paraseptal
 - Extended
 - Sublabial transseptal
 - Endonasal rhinoseptal
 - Transethmoid
- Transcranial
 - Subfrontal
 - Pterional

TSPH : Set up and instruments

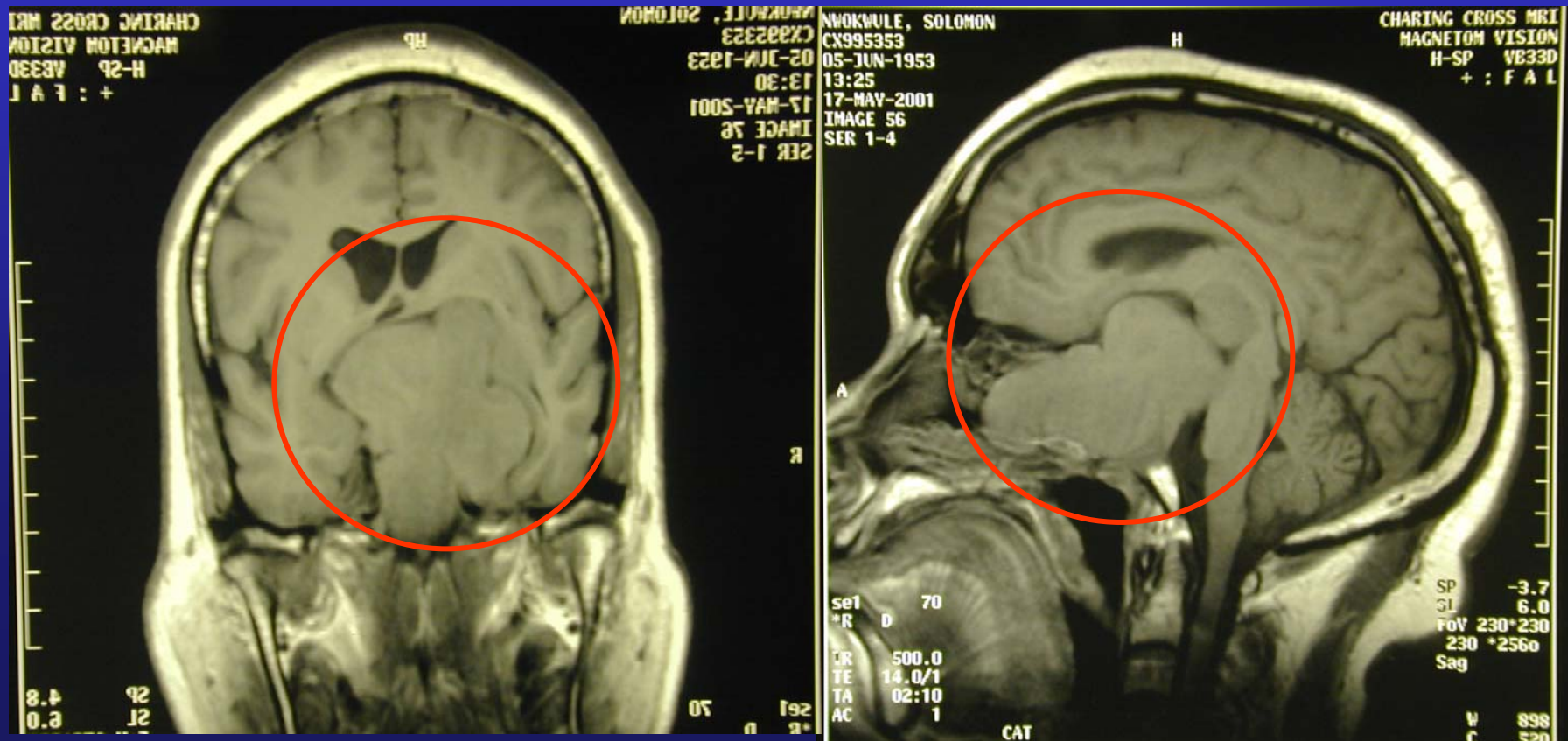


Transnasal paraseptal approach



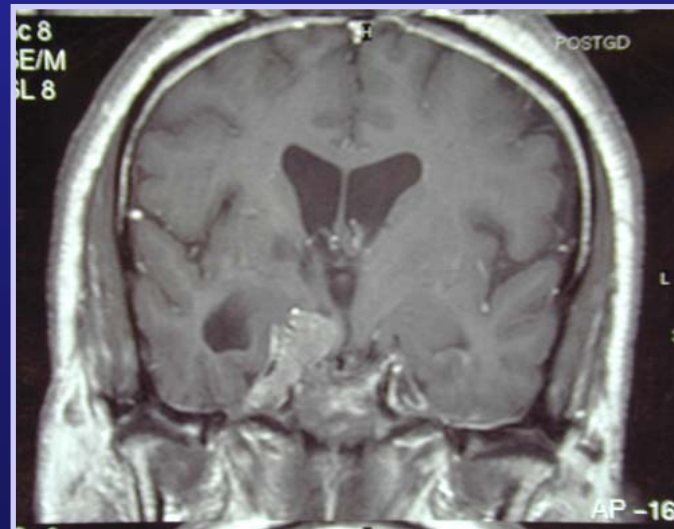
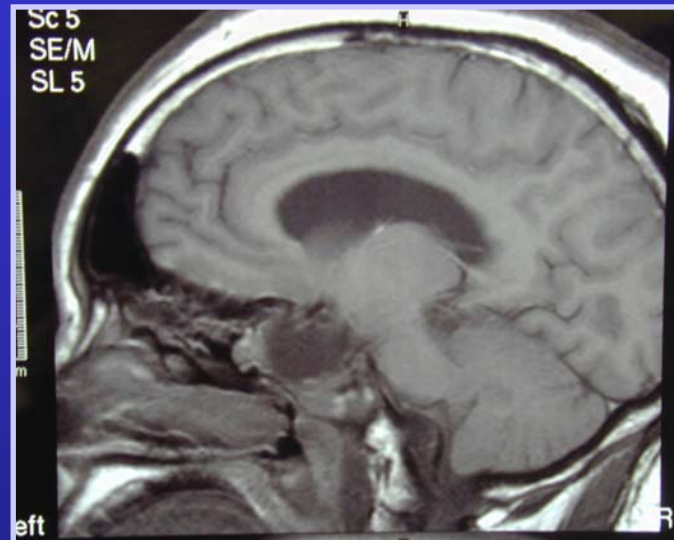
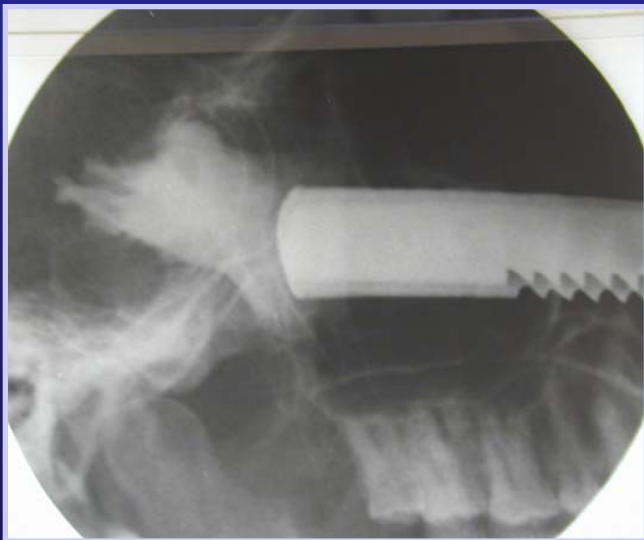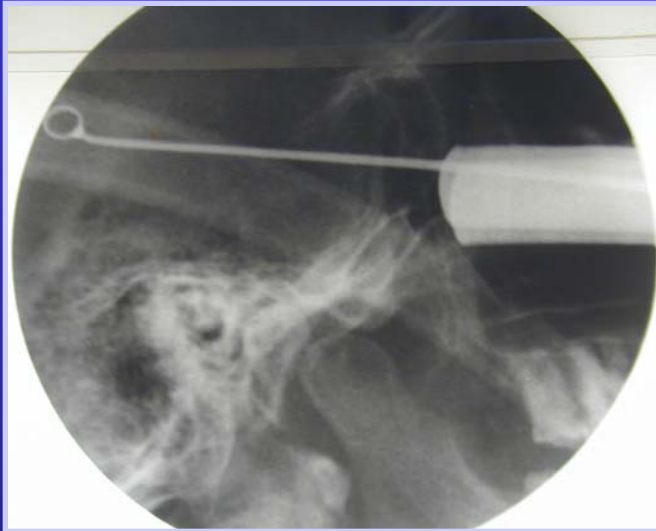
Non - functioning pituitary adenoma

49 yr old male with panhypopituitarism, blindness, and hemiparesis



Non - functioning pituitary macroadenoma

Peri- and post op imaging



Pituitary apoplexy

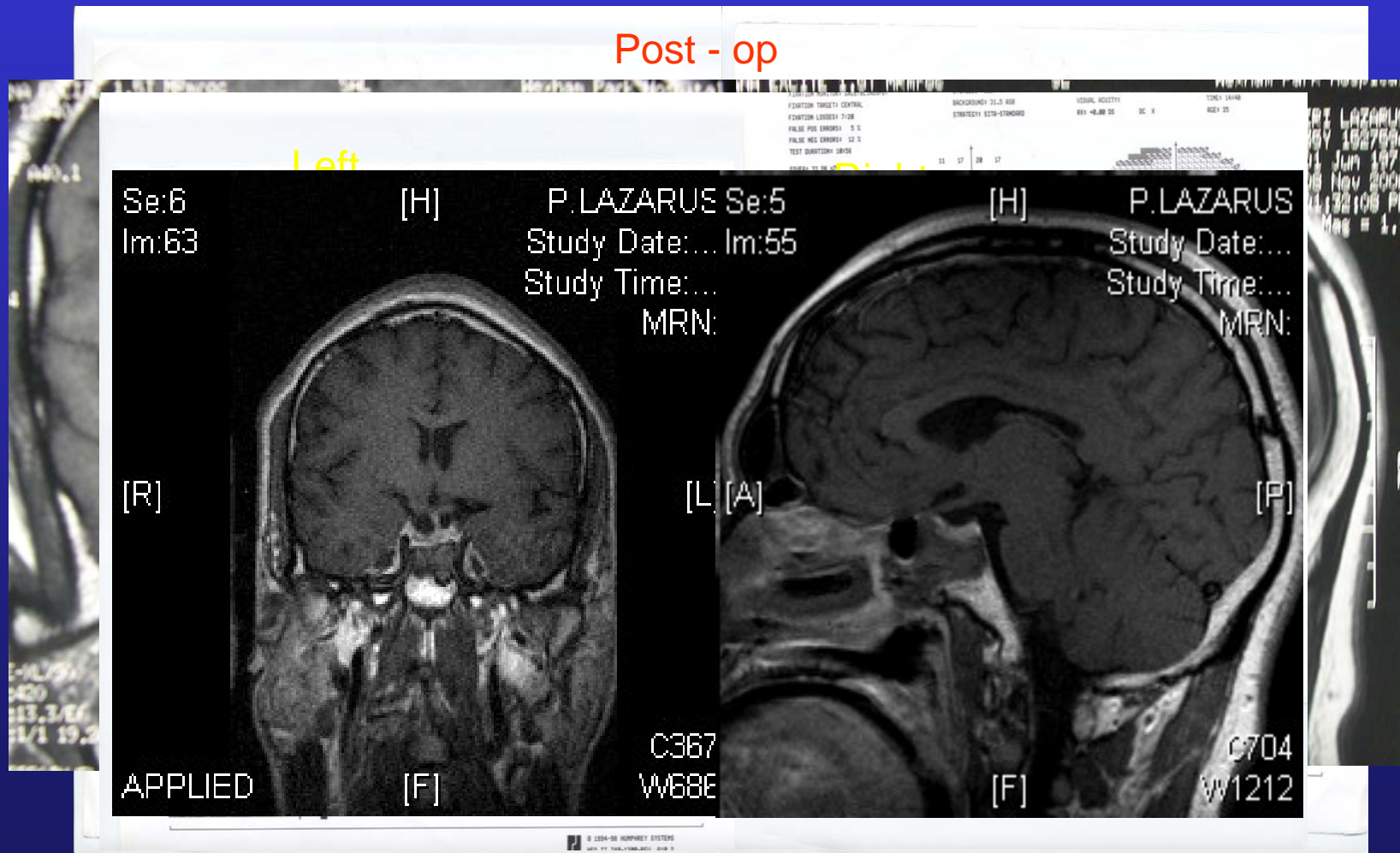
LP 35yr male with acute headache and visual loss

Left

Pre - op

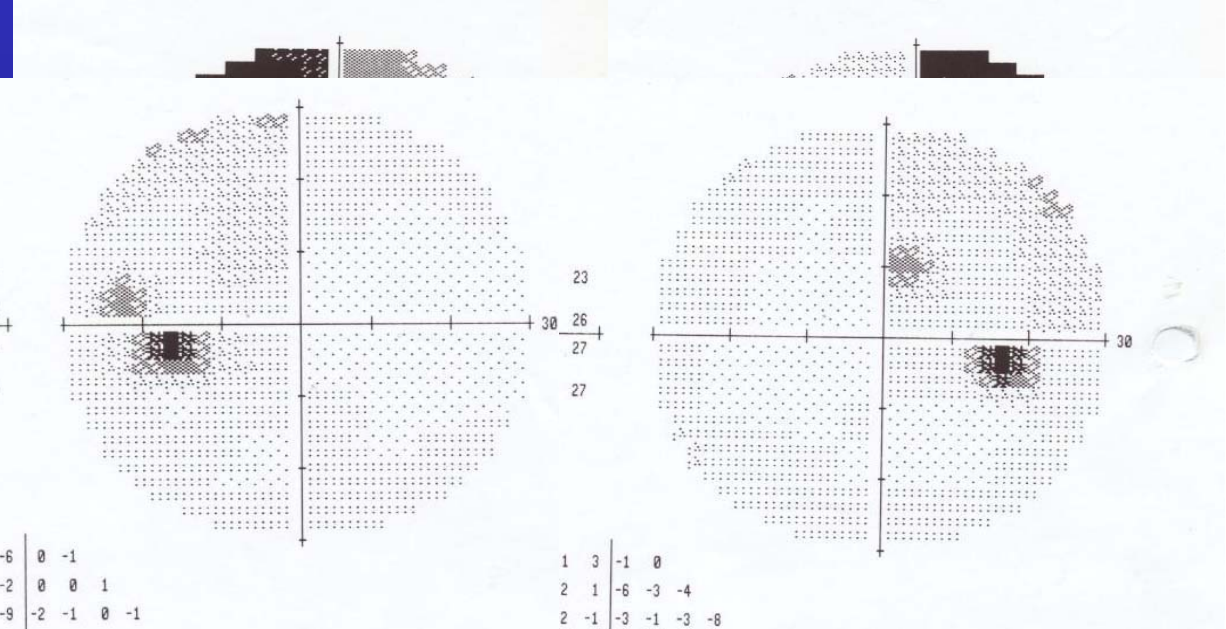
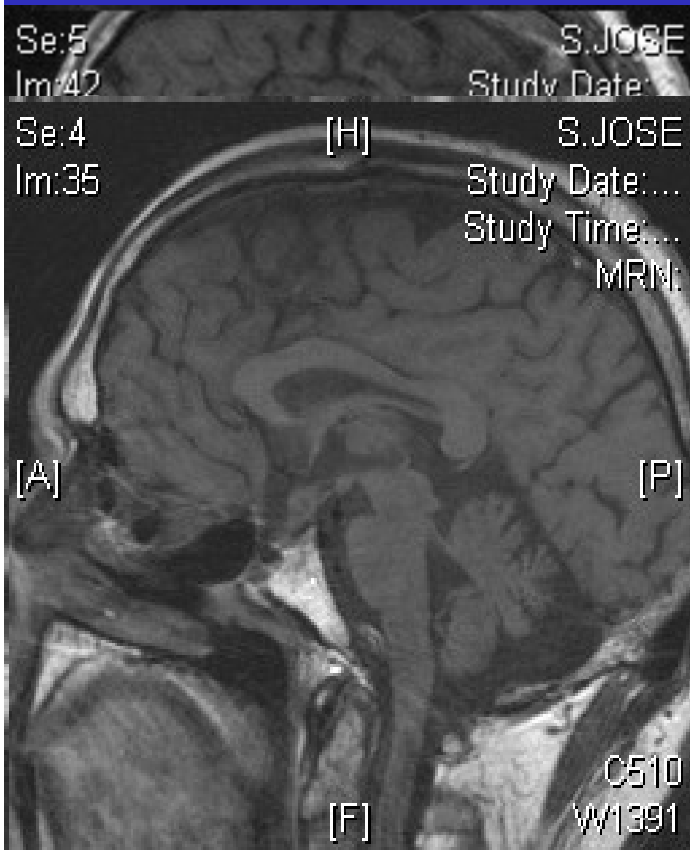Right

Post - op



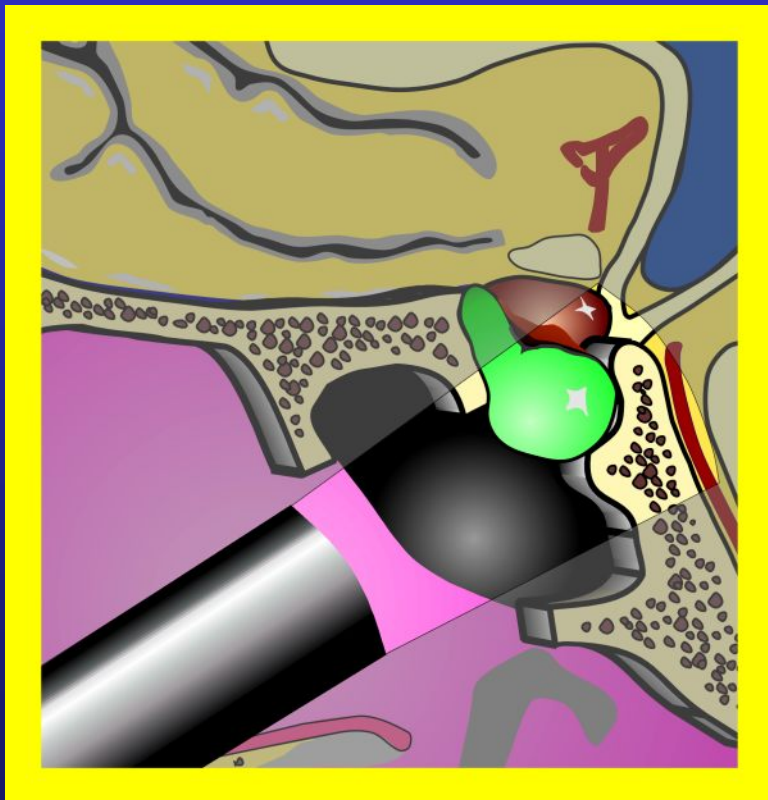
Rathkes Cleft cyst

J.S. 47 yr male progressive loss of vision



Endoscopic endonasal transphenoidal surgery

PubMed : 'Endoscopic transphenoidal pituitary surgery' : 120 publications 1978 - 2006



Advantages

Improved illumination

Improved vision – 0° / 30° rigid endoscope

Less nasal complications

Revision surgery / normal pituitary fossa

? Improved tumour resection

?? Improved outcome

Disadvantages

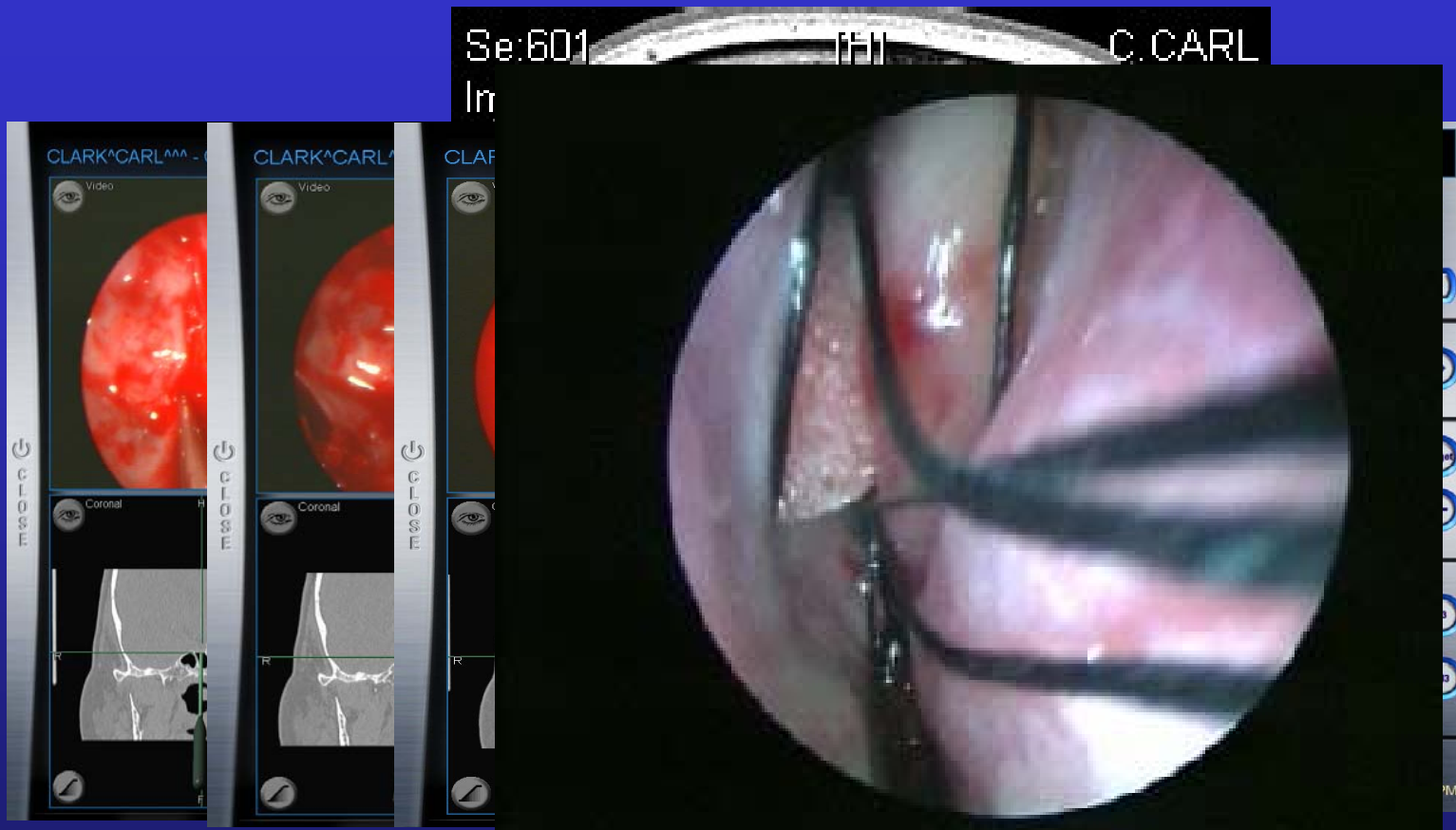
Learning curve

2 D view cf binocular microscope view

Instrumentation

Endoscopic endonasal assisted TSPH

C.C 38 male Cushings and Microprolactinoma



Endoscopic endonasal transphenoidal surgery. Jho H, Carrau. J. Neurosurg 87: 44-51, 1997

Surgical complications associated with the endoscopic transsphenoidal approach. Cappabianca et al. J. Neurosurg 97:293-298, 2002

Postoperative management

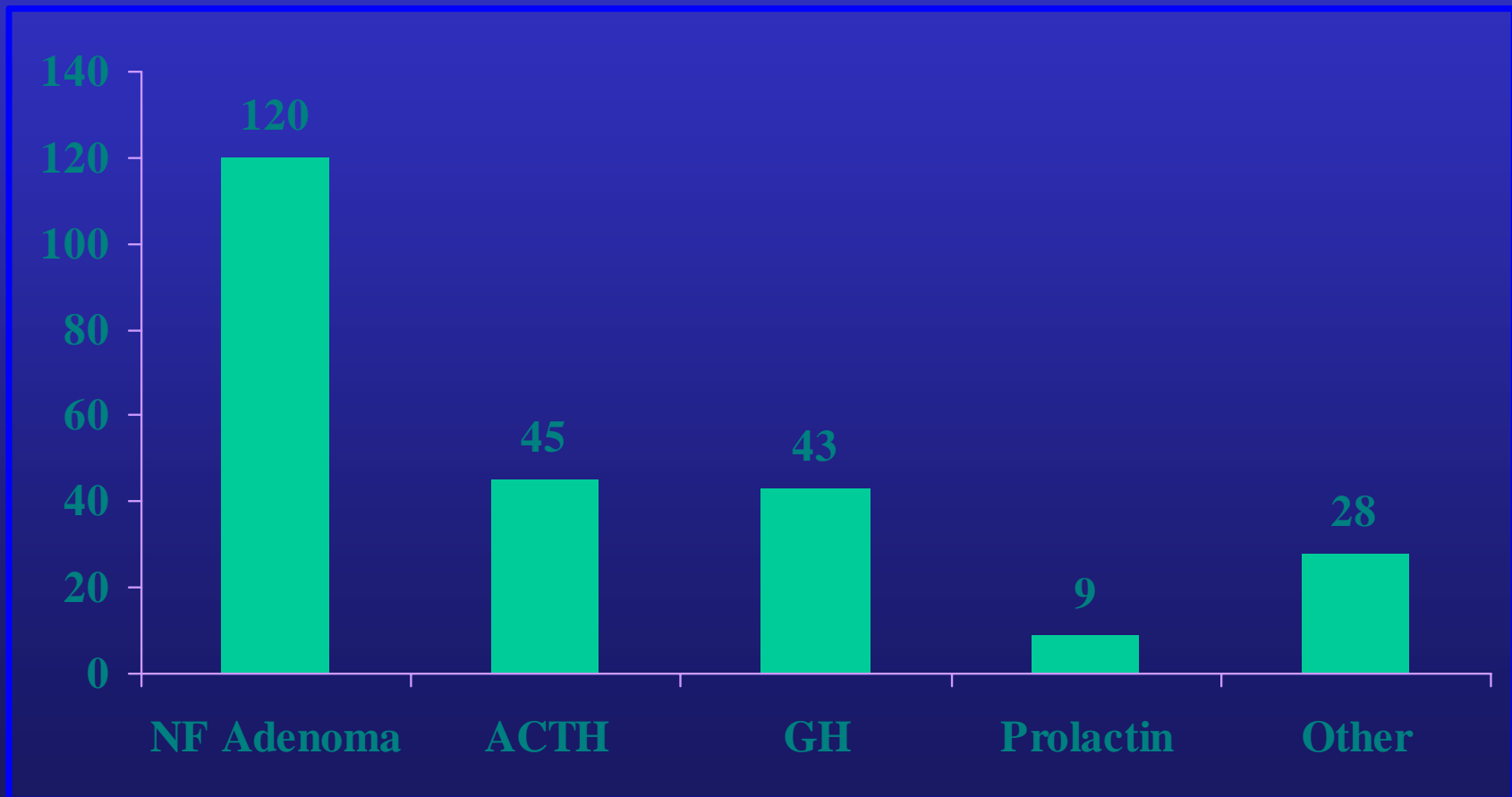
- IVI down at 24 hrs
- Packs out at 48 hours
- Continue replacement therapy
- Visual fields post op
- Home at day 2 post op
- Endocrine day case admission at 3-6 / 52
- OP clinic at 3 / 12 with post op MRI
- Cases discussed in monthly MDT

Monitoring and follow-up : Multidisciplinary team

- Hormonal status - Endocrinologist
- Visual fields - Orthoptist
- Monitor tumour recurrence - Radiologist
- Observation - Neurosurgeon
- Blood tests - Biochemist
- Irradiation - Radiotherapist

Tumours of the Sellar region : Charing Cross

Surgical series : 1995 - 2006



Cranial Base Surgery : Pituitary Tumours 1995 - 2006

- 245 operative procedures
 - 120 Chromophobe adenoma
 - 42 GH
 - 45 ACTHs
 - 9 Prolactinomas
 - 28 other
- Rathke cleft cyst 7
- Craniopharyngioma 4
- Metastasis 3
- Teratoma 2
- Germinoma 1
- Chordoma 1
- TSHoma 1
- MEN (ACTH/Pr) 1
- Glioma 1
- Pituicytoma 1
- Oncocytoma 1
- Xanthogranuloma 1
- Abscess 1
- Meningioma 1
- Chronic Lymphocytic Leukaemia 1
- CSF Fistula 1

RESULTS

Results : Visual recovery

Series	Nos	Recovery
Symon	101	57% full, 37% partial
Cohen	100	74% fields, 70% acuity
Findlay	34	85% improved
Laws	62	16.9% full 69% partial
Powell	67	34% full 43% partial
Mendoza	62	85% improved

Results : Acromegaly

Series	Nos	% Cure	Macro	Micro
Hardy	90	79	84	77
Laws	140	62		
Teasdale	56	46		
Landholt	169	70	76	64
Fahlbusch	227	57	81	65
Mendoza	27	50		80

Results : Cushings disease

Series	Nos	% Cure	Hypophysectomy
Tindall	56	84.9	9
Arnott	28	75	
Mamplan	221	76	25
Fahlbusch	101	74	
Cohen	8	50	2 nd procedure
Mendoza	45	80	

Fully endoscopic endonasal vs transseptal transphenoidal pituitary surgery

Keby MS, Eby JB, Shahinian HK. Minim Invasive Neurosurg. 2005; 48: 348-54

300 pts from 1998 – 2004 EETSS compared to historical series

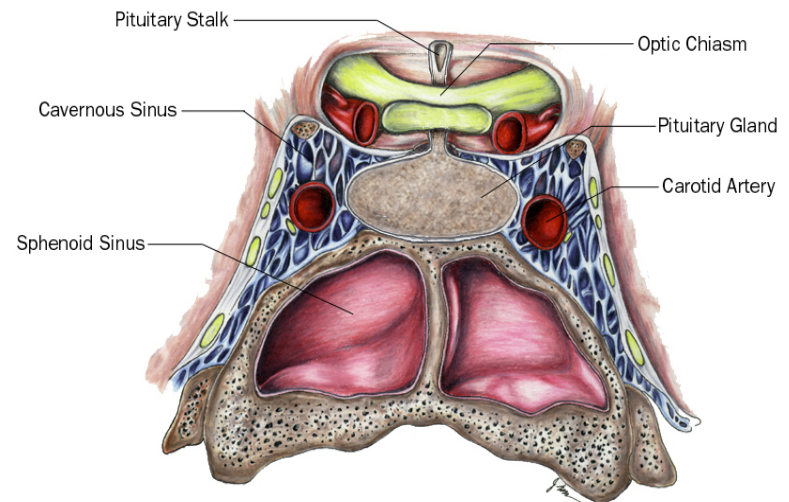
Av LOS : 1.4 days

54% Non – functioning , 46 % hormonally active

Mean f/u – 38.2 months

Remission	EETS	TSSS
NF	93%	90%
ACTH	86%	81%
GH	85%	77%
Prl	89%	66%

Complications



Surgical complications

- Nasal deformity
- Dry nose / anosmia
- Nasal perforation
- Visual loss
- Disturbance of pituitary function
 - Hypopituitarism
 - Diabetes insipidus
- CSF rhinorrhoea
 - Meningitis
- Haemorrhage
 - Tumour cavity
 - ICA
 - Cavernous sinus

Complications of transphenoidal surgery : Results of a national survey . *Ciric et al. Neurosurgery 40:225-237; 1997*

Septal perforation	6.7
Epistaxis	3.4
Sinusitis	8.5
Carotid artery injury	1.1
CNS injury	1.3
Haemorrhage into residual tumour	2.9
Loss of vision	1.8
Ophthalmoplegia	1.4
CSF leak	3.9
Meningitis	1.5
Ant. Pit. Deficiency	19.4
Diabetes insipidus	17.8
Death	0.9

Complications

- 5 transient CSF leaks
- 1 meningitis
- 1 hydrocephalus
- 1 ICA injury
- 1 post op intrasellar haematoma
- 3 deaths
 - 1 PE
 - 1 aneurysmal SAH
 - 1 moribund on admission

Summary

- Transphenoidal pituitary surgery is safe and effective
- Treatment options are best considered in a multidisciplinary setting
- Neurosurgical units should have a subspecialist surgeon
- Recent innovations have not yet demonstrated improved outcome

Thank you